





# Cryotherapy in the paediatric airway: Indications, success and safety

Dirk Schramm<sup>1</sup>  | Nadine Freitag<sup>1</sup> | Karsten Kötz<sup>2</sup> | Ignacio Iglesias-Serrano<sup>3</sup> | Mario Culebras-Amigo<sup>4</sup> | Vladimir Koblizek<sup>5</sup> | Santiago Pérez-Tarazona<sup>6</sup> | Enrique Cases Viedma<sup>7</sup> | JT Srikanta<sup>8</sup> | Peter Durdik<sup>9</sup>  | Kaid Darwiche<sup>10</sup>  | Sune Rubak<sup>11</sup> | Patrick Stafler<sup>12,13</sup> 

<sup>1</sup>Department of General Pediatrics, Neonatology and Pediatric Cardiology, Medical Faculty, University Hospital Düsseldorf, Heinrich-Heine-University Düsseldorf, Düsseldorf, Germany

<sup>2</sup>Queen Silvias Children Hospital, Sahlgrenska University Hospital, Gothenburg, Sweden

<sup>3</sup>Unitat de Pneumologia Pediàtrica i Fibrosi Quística, Hospital Universitari Vall d'Hebron, Barcelona, Spain

<sup>4</sup>Servei de Pneumologia, Hospital Universitari Vall d'Hebron, Barcelona, Spain

<sup>5</sup>Department of Pneumology, University Hospital Hradec Kralove, Faculty of Medicine in Hradec Kralove, Charles University, Prague, Czechia

<sup>6</sup>Pediatric Pulmonology Unit, La Fe University and Polytechnic Hospital, Valencia, Spain

<sup>7</sup>Respiratory Endoscopy Unit, La Fe University and Polytechnic Hospital, Valencia, Spain

<sup>8</sup>Pediatric Interventional Pulmonology, Allergy and Sleep Medicine, Aster CMI and RV Hospitals, Bengaluru, India

<sup>9</sup>Pediatric Department, University Hospital Martin, Jessenius Faculty of Medicine in Martin, Comenius University in Bratislava, Martin, Slovakia

<sup>10</sup>Department for Interventional Pneumology, Ruhrlandklinik—West German Lung Center, University Medicine Essen, Essen, Germany

<sup>11</sup>Department of Pediatrics and Adolescents Medicine, Danish Center of Pediatric Pulmonology and Allergology, University Hospital of Aarhus, Institute of Clinical Medicine, University of Aarhus, Aarhus, Denmark

<sup>12</sup>Pediatric Pulmonology Institute, Schneider Children's Medical Center of Israel, Petach Tikva, Israel

<sup>13</sup>Sackler Faculty of Medicine, Tel Aviv University, Tel Aviv, Israel

## Correspondence

Dirk Schramm

Email: [dirk.schramm@med.uni-duesseldorf.de](mailto:dirk.schramm@med.uni-duesseldorf.de)

**Associate Editor:** Stacey Peterson-Carmichael;

**Senior Editor:** Phan Nguyen

## Abstract

**Background and objective:** Cryotherapy in interventional bronchoscopy is a new treatment modality, which has recently been made available for the paediatric airway. Lack of experience and safety concerns have led to hesitant adaptation. The aim of this study was to assess indications, success rates and complications of airway cryotherapy in children.

**Methods:** Bronchoscopists from medical centre performing cryotherapy in patients between 0 and 18 years were invited to participate in a prospective study based on an online questionnaire. Patient and participant data were collected between June 2020 and June 2021.

**Results:** A total of 69 cryotherapy procedures were performed in 57 patients for three main indications: Biopsy (30), restoration of airway patency (23) and foreign body aspiration (16). The overall success rate was 93%, the remaining 7% were performed for foreign body removal and required a switch of technique. Restoration of airway patency was successfully applied in various pathologies, including mucus plugs, bronchial casts and post traumatic stenosis. The diagnostic yield of transbronchial biopsies was 96%. No severe complications were encountered; one pneumothorax following a cryobiopsy required a chest drain for 48 h. No child was admitted to intensive care or died from a procedural complication.

This is an open access article under the terms of the [Creative Commons Attribution-NonCommercial](https://creativecommons.org/licenses/by-nc/4.0/) License, which permits use, distribution and reproduction in any medium, provided the original work is properly cited and is not used for commercial purposes.

© 2022 The Authors. *Respirology* published by John Wiley & Sons Australia, Ltd on behalf of Asian Pacific Society of Respiriology.

**Conclusion:** In this largest paediatric case collection to date, cryotherapy was safe and carried a high success rate. Cryobiopsy compares favourably to the widely used forceps biopsy and could replace it in the future. Paediatric bronchoscopists are encouraged to add cryotherapy to their armamentarium of airway interventions.

**KEYWORDS**

airway obstruction, cryotherapy, cryobiopsy, foreign body removal, interventional bronchoscopy, paediatric bronchoscopy

## INTRODUCTION

Cryotherapy is a new diagnostic and therapeutic tool that has recently been made available for the paediatric airway. The development of cryoprobes as small as 1.1 mm has paved the way for its use in children of all age groups and opens new opportunities in interventional paediatric airway endoscopy.

Cryotherapy was first performed in the mid-1800s to relieve pain and stop the bleeding of skin tumours by applying ice-salt solution.<sup>1</sup> Since then, a wide range of applications have been discovered in pulmonology, including endobronchial biopsy (EBB) and transbronchial biopsy (TBB), restoration of airway patency and foreign body removal. Compared to the early days of cryotherapy, today's devices use nitrogen, nitrous oxide or carbon oxide as cryogens and facilitate cooling down to approximately  $-50^{\circ}\text{C}$  at the tip of the probe. The formation of ice-crystals disrupts cell organelles and fluid shifts dehydrate cells. Additionally, the low temperatures lead to local vasoconstriction and thrombosis.<sup>2</sup>

Due to its novelty, data on cryotherapy in children is scarce.<sup>3,4</sup> The standard of care for TBB in paediatric patients is to perform it by forceps,<sup>5</sup> with complication rates ranging between 2.3% and 7.9% including pneumothorax, bleeding and postprocedural sepsis.<sup>6,7</sup> No accepted standard of care exists for EBB or surgical wedge biopsy. In adults, a recent shift towards cryobiopsy can be observed.<sup>8</sup> Restoration of airway patency using cryo has been described more frequently in children<sup>9</sup> and for a variety of pathologies, such as plastic bronchitis<sup>10,11</sup> tracheal stenosis,<sup>12,13</sup> and the recanalization of obstructed bronchial stents.<sup>14</sup> Additionally, the removal of bronchial mucoepidermoid carcinoma in six patients<sup>15</sup> and the debulking of an inflammatory myofibroblastic tumour<sup>16</sup> have been reported. Removing organic and inorganic foreign bodies using cryotherapy has successfully been reported in a study comprising 12 children<sup>17</sup> and in two case reports.<sup>18,19</sup>

Although to date, no serious complications related to cryotherapy in children have been reported, caution is indicated. In the adult literature, Davidsen et al. found a death rate of 0.3%–1.4% within 30 days of the procedure. They reported minor bleeding in 83.7%, moderate bleeding in 16.3% and pneumothorax in 14.9% of the cases. This must be viewed through the prism of higher morbidity and a very different set of indications in this population. Of note, no procedure-related deaths were documented.<sup>20</sup> Cryotherapy

seems to be a promising new technique for paediatric airway endoscopy suited for a wide range of indications. However, due to the novelty, lack of experience and safety concerns, there is hesitation about its applicability in the paediatric airway,<sup>21</sup> which has led the European Respiratory Society to call for studies addressing the role of cryotherapy in children.<sup>22</sup>

The aim of this multicentre study was to collect pulmonary cryotherapy cases involving children and report indications, techniques, success rates, as well as complications.

## METHODS

### Study design

We conducted a prospective multicentre study, inviting paediatric pulmonologists who use airway cryotherapy to contribute cases via an online questionnaire. The study was announced via various professional forums and national societies. Data were obtained from 10 medical centres, located in eight countries and two continents between June 2020 and June 2021 via the 'EvaSys' survey tool (Lüneburg, Germany). The questionnaire collected data on the extent of cryotherapy experience of the bronchoscopist, centre size, indication, patient characteristics, success rate, complications and technical details. Complications were classified as severe if the bronchoscopy had to be aborted; this decision was based on a safety evaluation performed by both the bronchoscopist as well as the anesthetist. The bronchoscopists remained anonymous and assured that every consecutive case encountered was included in the study and that good scientific practice guidelines were followed.

### Subjects

Patients between 0 and 18 years of age who underwent cryotherapy during airway endoscopy were included in the study.

### Statistical analysis

Statistical analysis was performed using SPSS Statistics (IBM, USA). Descriptive analysis was conducted for demographic data, indications, complications and success rates.

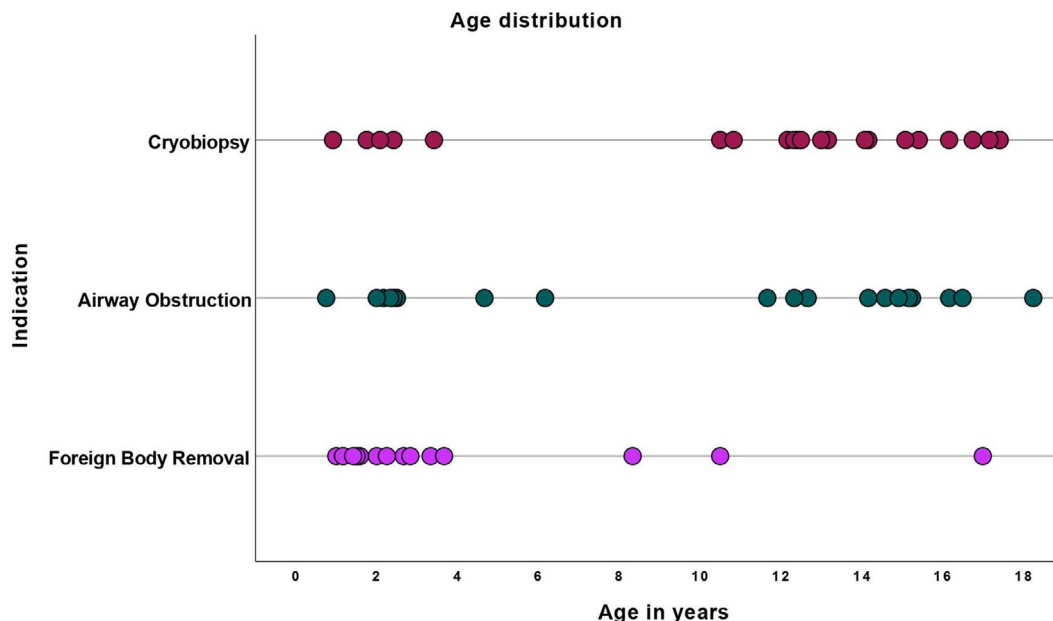


FIGURE 1 Age distribution in children undergoing cryotherapy ( $N = 57$ ). Children are grouped according to the indication for their cryotherapy procedure, each coloured dot represents one patient.

When multiple procedures were included for a patient, the initial procedure was used for demographic analysis.

Independent *t*-test was performed to compare the means of two unrelated samples; Welch's *t*-test was used to determine differences between the means in two unrelated samples with unequal variances.<sup>23</sup> Continuous data are presented as mean  $\pm$  SD or median and range  $\pm$  interquartile range (IQR); categorical data as number (percentage).

## RESULTS

### Study population

Data was obtained on 57 patients who underwent a total of 69 cryotherapy procedures at a median age of 10.5 ( $\pm$  12.5 IQR) years. One patient underwent six cryotherapy procedures, another patient three and five patients two procedures each.

There were three distinct indications for the performance of cryotherapy, the most frequent of which was cryobiopsy, undertaken in 22 children at a median age of 12.8 ( $\pm$  6.9 IQR) years. Twenty children underwent cryotherapy for restoration of airway patency, at 12.3 ( $\pm$  12.8 IQR) years of age and sixteen for foreign body removal, at 2.1 ( $\pm$  2.2 IQR) years of age.

Children undergoing foreign body removal were significantly younger than those with airway obstruction ( $t[32.07] = -3.233$ ,  $p = 0.003$ ) and those requiring cryobiopsy ( $t[36] = -4.5$ ,  $p < 0.001$ ). Children with airway obstruction and cryobiopsy showed two age peaks as shown in Figure 1.

TABLE 1 Diagnoses obtained and underlying aetiologies

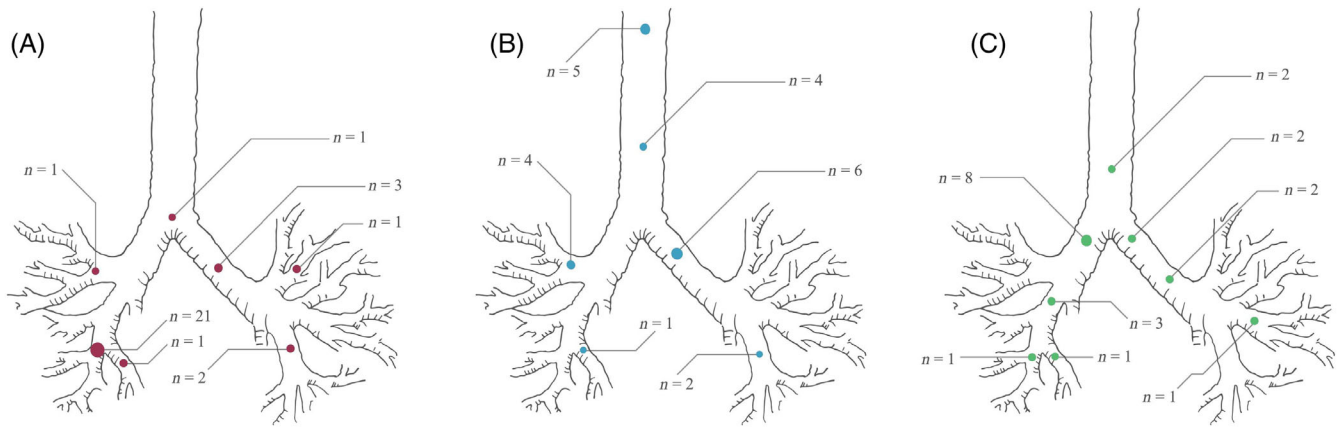
	<i>n</i> = 30	%
Cryobiopsy		
Follow-up after lung transplantation	12	40
Interstitial lung disease <sup>a</sup>	12	40
Carcinoid tumour	3	10
Sarcoidosis	2	6.7
Chronic erosive tracheobronchitis	1	3.3
Airway obstruction	<i>n</i> = 23	
Granulation tissue	9	39.1
Mucus plugs from cystic fibrosis	5	21.7
Endotracheal tumours	4	17.4
Plastic bronchitis	2	8.7
Foreign bodies	<i>n</i> = 16	
Nuts and seeds	9	56.3
Pieces of carrot	3	18.8
Muesli flake/piece of muesli bar	2	12.5
Pen cap	1	6.2
Tuberculous focus (confirmed by pathology unit)	1	6.2

Note: Diagnoses that were obtained from 30 cryobiopsies, underlying aetiologies in 23 cases of airway obstruction and nature of the foreign body in 16 cases.

<sup>a</sup>Subtypes of interstitial lung diseases included: antisynthetase syndrome, ABCA3 mutation, Idiopathic pulmonary hemosiderosis, primary alveolar proteinosis, nonspecific interstitial pneumonia due to surfactant protein C deficiency and nonspecific interstitial pneumonia associated with undifferentiated connective tissue disease.

Diagnoses obtained from cryobiopsies, underlying aetiology of airway obstruction and the nature of foreign bodies can be found in Table 1.

The time interval between aspiration of the foreign body and the cryotherapy intervention was 0–24 h in six cases



**FIGURE 2** Anatomical location of cryobiopsies (A), airway obstructions (B) and foreign bodies (C). Graphical illustration of the anatomical location of 69 cryotherapy procedures in 57 patients between 0 and 18 years of age. The size of the circles represents the weighted number of procedures carried out in the respective location.

**TABLE 2** Technical characteristics of the cryotherapy procedures ( $n = 69$ )

	Cryobiopsy $n = 30$	Airway obstruction $n = 23$	Foreign body $n = 16$
Type of bronchoscope			
No. flexible (%)	28 (93.3)	16 (69.6)	12 (75)
No. rigid (%)	2 (6.7)	6 (26.1)	3 (18.8)
No. missing values (%)	0	1 (4.3)	1 (6.3)
Bronchoscope size			
Median (mm)	6.2	4.9	4.1
Range (mm)	4.0–8.2	3.1–6.2	2.8–6.2
No. missing values (%)	1 (3.3)	6 (26.1)	2 (12.5)
Cryo probe size			
Median (mm)	1.9	1.9	1.9
Range (mm)	1.1–2.4	1.1–2.4	1.1–2.2
No. of missing values (%)	1 (3.3)	9 (39.1)	3 (18.8)
Cryogen			
No. CO <sub>2</sub> (%)	24 (80)	11 (47.8)	11 (68.8)
No. N <sub>2</sub> O (%)	5 (16.7)	3 (13)	2 (12.5)
No. missing values (%)	1 (3.3)	9 (39.1)	3 (18.8)
Duration of freezing			
Median (s)	3.5	10	5
Range (s)	3–5	5–20	3–20
No. missing values (%)	2 (6.7)	9 (39.1)	3 (18.8)
Temperature of freezing			
Mean (°C)	- 87.4	-64.6	-83.3
Standard deviation (°C)	2.6	21.5	16.4
No. missing values (%)	2 (6.7)	11 (47.8)	4 (25)
Number of freeze/thaw cycles			
Median	3	3	/
Range	1–5	3–10	/
No. of missing values	1 (3.3)	12 (52.2)	/

Note: In 57 patients, between 0 and 18 years 69 cryotherapy procedures were performed for biopsies, airway obstruction or foreign bodies. Abbreviations: CO<sub>2</sub>, carbon dioxide; N<sub>2</sub>O, nitrous oxide; No., number of.

(37.5%), 24 h to 7 days in four cases (25%) and more than 7 days in three cases (18.8%); no information regarding time delay was available in the remaining three cases (18.8%).

## Technical specifications

Figure 2 shows the frequency of the respective procedures, according to their anatomical locations in the airway. Out of 30 cryobiopsies, 21 (70%) were taken from the right lower lobe with the aim of diagnosing the aetiology of diffuse lung disease. Foreign bodies equally showed a predilection for the right lung. Restoration of airway patency was mainly performed in the trachea (nine cases, 39.1%) for post intubation/tracheostomy site stenosis or the left main bronchus/left lower lobe (eight cases, 34.8%).

We further collected technical characteristics of the cryotherapy procedures as displayed in Table 2. The majority of all procedures were performed with a flexible bronchoscope (56/67 cases with information, 83.6%). The most common cryoprobe size was 1.9 mm (21/57 cases with information, 36.8%) and carbon dioxide was the predominant cryogenic gas (46/57 cases with information, 80.7%). The duration of freezing was significantly longer in cases of airway obstruction compared to foreign body removal ( $t[-2.94] = 17.78$ ,  $p = 0.009$ ) and cryobiopsy ( $t[9.64] = 10.08$ ,  $p < 0.001$ ).

## Success and complication rates

Out of 69 cryotherapy procedures, 64 (93%) were subjectively rated 'successful' by the respective bronchoscopist. The five cases deemed 'unsuccessful' were performed for foreign body removal (total procedures  $n = 16$ ) due to a requirement to switch to another technique. Removal of the foreign body failed either due to low cryoadhesion of the foreign body or inadequate accessibility. Additional equipment used were rigid bronchoscope, retrieval basket, forceps or balloon bronchial blocker.

In the subset of 30 cryobiopsies, 24 (80%) were TBBs and six (20%) EBBs. A sample was macroscopically present

in all cases and histopathological evaluation was successful in 28 cases (93.3%), resulting in a diagnostic yield of 95.8% in TBB and 83.3% in EBB. Three cases (10%) were performed with a probe size of 1.1 mm outer diameter (OD); all of which resulted in a successful histopathological evaluation.

For the treatment of airway obstruction, 23 cryotherapy procedures were performed in 20 patients. In five patients with cystic fibrosis and mucus plugs, cryotherapy was combined with an Arndt balloon bronchial block for airway dilatation. Tumour debulking with cryotherapy was supported by forceps, Argon photo coagulation and electrocautery in two out of three cases. In one out of eight cases of airway stenosis, dilatation by a bougie was additionally used. In total, cryotherapy for the treatment of airway patency was used in conjunction with other modalities in 50% of the cases. Information about the improvement in airway diameter were available in 12/23 cases. In these, a median (range) increase of 85% (10%–99%) in luminal diameter was achieved. Clinical symptoms improved in all cases and patency was completely restored in 12 out of 17 procedures (70.6%).

In regard to complication rates, superficial mucosal bleeding requiring no intervention was frequent for each of the three indications, occurring in 32/69 cases (46.4%). Bleeding that required local application of vasoactive substances such as cold saline serum or naphazoline occurred in 12 cases (17.4%), eight were performed for cryobiopsy (7 TBB and 1 EBB) and three were performed for the debulking of carcinoid tumours. In none of the cases, the procedure had to be interrupted for the intervention. A transient bronchospasm was observed once, during cryobiopsy, and did also not require interruption of the procedure. Following two cryobiopsies, pneumothoraces were observed, one of which required a chest drain for 48 h.

Overall, no severe complications were recorded in any of the 69 cases of cryotherapy. Two cases of pneumothoraces were encountered of which one required a chest drain. One transient bronchospasm occurred. Table 3 provides an overview of the complications associated with cryotherapy.

There was no necessity for emergency follow-up bronchoscopies or intensive care admission and no child passed

**TABLE 3** Complications associated with cryotherapy procedures ( $n = 69$ )

	Foreign body removal		Airway obstruction		Biopsy		Total	
	$n = 16$	%	$n = 23$	%	$n = 30$	%	$n = 69$	%
Superficial mucosal bleeding	6	37.5	11	47.8	15	50	32	46.4
Bleeding requiring local application of vasoactive substances	0	0	3	13	8	26.7	11	15.9
Pneumothorax	0	0	0	0	2	6.7	2	2.9
Bronchospasm	0	0	0	0	1	3.3	1	1.4
Airway ulceration/perforation	0	0	0	0	0	0	0	0
Technical difficulties	0	0	0	0	0	0	0	0
Death	0	0	0	0	0	0	0	0

Note: Complications that were associated with the 69 cryotherapy procedures performed in 57 children between 0 and 18 years, according to indications.

TABLE 4 Bronchoscopists profile (*n* = 69)

		Paediatric pulmonologists		Adult pulmonologists		Otolaryngologist	
		<i>n</i> = 40	%	<i>n</i> = 28	%	<i>n</i> = 1	%
Average no. flexible bronchoscopies per year	0–100/yr	14	35	0	0	1	100
	101–998/yr	26	65	3	10.7	0	0
	≥999/yr	0	0	25	89.3	0	0
No. cryotherapy procedures (total amount prior to the procedure)	0	1	2.5	0	0	1	100
	1–100	39	97.5	0	0	0	0
	101–998	0	0	16	57.1	0	0
	≥999	0	0	12	42.9	0	0
No. cryotherapy procedures (total amount prior to the procedure in adults ≥18 years)	0	28	70	0	0	1	100
	1–100	11	27.5	0	0	0	0
	101–998	1	2.5	17	60.7	0	0
	≥999	0	0	11	93.3	0	0

Abbreviations: No., number of; yr, year.

away related to cryotherapy. In eight cases (11.6%), a flexible bronchoscopy was electively performed within 1 week of the initial cryotherapy procedure. These investigations were undertaken as follow-up for airway patency restoration (5), foreign body removal (2) and cryobiopsy (1).

## Examiner profile

Out of the 69 procedures, 40 (58%) were performed by paediatric pulmonologists, 28 (40.6%) by adult pulmonologists and 1 (1.4%) by an otolaryngologist.

As displayed in Table 4, adult pulmonologists were on average more experienced with flexible bronchoscopy and had performed more cryotherapy procedures prior to the included procedure than paediatricians (Table S1).

## DISCUSSION

In this largest paediatric case collection to date, airway cryotherapy was safe and carried a high success rate.

The commonest indication in our sample was cryobiopsy. At an adequate tissue sampling rate of 100% and diagnostic yield of 95.8%, cryo TBB compares favourably to the limited paediatric data concerning forceps TBB, suggesting adequate tissue sampling in ~90% with diagnostic yield of only ~55%.<sup>22</sup> The higher diagnostic yield in our cryobiopsy sample is likely related to the larger tissue size, as well as avoidance of crush artefacts. Indeed, adult TBB practice has seen a shift from forceps to cryo over the last few years.<sup>24–27</sup>

At 10%, the complication rate in our cryo TBB series was similar to that reported in the context of forceps TBB.<sup>6,7</sup> As the tip of the probe is not visible during transbronchial cryobiopsy procedures, caution ought to be exerted with regards to the freeze time, to avoid excessive tissue damage

as the ice ball expands. This has been pointed out in a pivotal expert statement, advising that limiting freeze time reduces complication rates whilst preserving diagnostic yield.<sup>28</sup> The current recommendation in adult pulmonology is to use an advanced airway, reduce freezing time to 3–4 s and limit the number of samples.<sup>29</sup> Whether these recommendations are transferable to the paediatric population cannot be entirely answered. Nevertheless, the 3.5 s mean freezing time in our study is in keeping with the adult recommendations and the low complication rate of our study indicates that a similar freezing time might be appropriate for children.

Cryotherapy to restore airway patency was applied for a wide variety of pathologies, including nine cases of post tracheostomy tracheal stenosis. Compared to more established techniques, for example, endoscopic balloon dilatation, achieving success rates between 60% and 70%,<sup>30</sup> the success rate of 100% in our series is impressive. However, since the definition of ‘success’ varies between studies, our rate, relating to clinically important increase in diameter might be overly optimistic. It must moreover be borne in mind that our data is limited to the short term and did not record restenosis rates. Nonetheless, experience with cryotherapy in benign strictures suggests there might be a remodelling effect to the connective tissue matrix that may contribute to a greater malleability and therefore less traumatic dilatation.<sup>31,32</sup> Furthermore, dermatological research indicates superiority of tissue healing from freeze injuries, in comparison to burn injuries.<sup>33</sup> It is believed that contraction does not occur in the healing of freeze injuries due to slow replacement of residual matrix, which might prevent restenosis.<sup>33,34</sup> In comparison to laser-assisted dilatation, cryotherapy also avoids the risk of endobronchial fires.<sup>35,36</sup> In our cohort, no complications apart from mild mucosal bleeding were observed.

In all cases of tenacious mucus plugs in cystic fibrosis and eosinophilic casts, cryotherapy removal led to improvement

of clinical symptoms and recruitment of atelectasis. No complications were recorded in any of the cases. Removal of mucus plugs or bronchial casts have traditionally been carried out using suction, aided by instillation of mucolytics, such as hypertonic saline, DNase and tissue plasminogen activator.<sup>37</sup> Additionally, there are reports about forceps extraction of casts.<sup>38</sup> Sriratanaviriyakul et al. reported on adult patients with airway impaction caused by blood clots, mucus plugs or plastic bronchitis, safely treated by cryotherapy extraction.<sup>39</sup> Comparable drug therapy offers a variety of options such as corticosteroids, macrolide antibiotics or sirolimus; however, no single medication has been shown to effectively treat patients with plastic bronchitis.<sup>37</sup> In keeping with existing literature,<sup>39</sup> our results show cryotherapy to be a safe and highly effective new method for mucus plug or cast removal in the peripheral airways of children.

The third main indication for cryotherapy was foreign body retrieval, recorded in 16 cases. Although only 69% of foreign body retrieval procedures were classified as 'successful', all but one foreign body were ultimately retrieved successfully, with about a third requiring additional instruments. The need for a wide array of tools, ranging from rigid to flexible bronchoscope, as well as a variety of forceps, Fogarty catheters, baskets and others, is a well-recognized feature of foreign body retrieval.<sup>22</sup> When it comes to cryotherapy for foreign body retrieval, the nature of the foreign body and its water content will to some extent determine the likelihood of success with the cryoprobe.<sup>40</sup> It is therefore not surprising that cryotherapy does not offer a 100% success rate in and of itself. A previous case series, describing 12 paediatric patients with aspirated foreign bodies who were treated with cryotherapy,<sup>17</sup> came to very similar conclusions. The procedure was successful in 67%, loss of foreign body occurred in one case and failure to reach the foreign body in one patient. In our series, no serious complications were recorded in any of the 16 cases. The comparison of success and complication rates between cryotherapy and other techniques for foreign body extraction in the paediatric airway is fraught with difficulty, owing to scarcity of data and the intrinsic limitation of the usually retrospective study designs; in particular with regards to technical failures and the need to switch to other techniques.<sup>41–43</sup> The skilled interventional bronchoscopist of the future will have to be familiar with a wide variety of instruments, including the cryoprobe, to adequately address each and every challenge based on foreign body consistency, location and size of the airway.

Our study has three major limitations. First, the patient cohort is very heterogenous with regards to their underlying diagnoses and indications for cryotherapy, resulting in rather small sample sizes for each of the main indications. Nonetheless, the heterogeneity powerfully shows the wide range of areas for application of cryotherapy in children. Secondly, the observational design of our study limits its validity in comparison to a large clinical trial with case controls. A potential recall bias might have occurred if the bronchoscopist entered the data from memory instead of the patient file. Finally, bronchoscopists were requested to

consecutively enrol and report each case of cryotherapy performed during the data collection period. Even though anonymity was provided to the bronchoscopists, selection bias cannot be entirely ruled out.

In summary, our study shows that cryotherapy in the paediatric airway offers a high success rate with few and well manageable complications. Cryobiopsy is a promising new technique for EBBs and TBBs. Due to its higher diagnostic yield and similar safety profile, it might well go to replace the widely used forceps biopsy in the near future. Cryotherapy further seems useful for restoration of airway patency, for example, for traumatic tracheal stenosis, endobronchial casts or mucus plugs and for the removal of foreign bodies. It is time to adapt airway cryotherapy into paediatric practice, ensuring adequate training of bronchoscopists, whilst continuing to monitor safety and success rates. Efforts are under way to address the lack of formal training in cryotherapy in the paediatric airway within international frameworks and this is to be highly encouraged.

#### AUTHOR CONTRIBUTION

**Nadine Freitag:** Formal analysis (lead); methodology (supporting); project administration (equal); writing – original draft (equal); writing – review and editing (supporting). **Karsten Kötz:** Data curation (equal); methodology (supporting); validation (equal); writing – review and editing (equal). **Ignacio Iglesias-Serrano:** Data curation (equal); writing – review and editing (equal). **Mario Culebras-Amigo:** Data curation (equal); writing – review and editing (equal). **Vladimir Koblizek:** Data curation (equal); writing – review and editing (equal). **Santiago Pérez-Tarazona:** Data curation (equal); writing – review and editing (equal). **Enrique Cases Viedma:** Data curation (equal); writing – review and editing (equal). **J. T. Srikanta:** Data curation (equal); writing – review and editing (equal). **Peter Durdik:** Data curation (equal); writing – review and editing (equal). **Kaid Darwiche:** Data curation (equal); writing – review and editing (equal). **Sune Rubak:** Data curation (equal); writing – review and editing (equal). **Patrick Stafler:** Conceptualization (supporting); data curation (equal); formal analysis (supporting); methodology (supporting); supervision (lead); writing – review and editing (lead). **Dirk Schramm:** Conceptualization (supporting); data curation (equal); methodology (supporting); writing – original draft (equal); writing – review and editing (supporting).

#### ACKNOWLEDGEMENT

The authors sincerely acknowledge the support of Selina Freitag in illustrating the figures. Open Access funding enabled and organized by Projekt DEAL.

#### CONFLICT OF INTEREST

None declared.

#### DATA AVAILABILITY STATEMENT

Data are available upon reasonable request. De-identified participant data are available from the corresponding author

upon reasonable request, subject to the terms of Research Ethics Committee approval. The questionnaire used for the study is available online as Supporting Information.

## HUMAN ETHICS APPROVAL DECLARATION

The study was approved by the Ethics Committee of the Heinrich-Heine University Düsseldorf, Germany (No. 2020-884) and informed consent was waived.

## ORCID

Dirk Schramm  <https://orcid.org/0000-0002-0440-4737>

Peter Durdik  <https://orcid.org/0000-0002-5813-3039>

Kaid Darwiche  <https://orcid.org/0000-0003-0681-1325>

Patrick Stafler  <https://orcid.org/0000-0001-8880-8212>

## REFERENCES

1. Arnott J. On the remedial and anæsthetic uses of intense cold. *Mon J Med Sci.* 1854;10:32–9.
2. Grant CSA. Cryotherapy. In: Goldfarb S, Piccione J, editors. *Diagnostic and interventional bronchoscopy in children.* (Respiratory Medicine). Cham: Springer International Publishing; 2021.
3. Srikanta JT, Swarna S, Shylendra DS, Mehta R. Transbronchial lung cryobiopsy for diagnosis of pediatric interstitial lung disease. *Indian Pediatr.* 2018;55:519–20.
4. Spencer CY, Millman J, Veiga K, Vicencio AG. Airway autoimmune inflammatory response (AAIR) syndrome: an asthma-autoimmune overlap disorder? *Pediatrics.* 2018;141:e20170138.
5. Faro A, Visner G. The use of multiple transbronchial biopsies as the standard approach to evaluate lung allograft rejection. *Pediatr Transplant.* 2004;8:322–8.
6. Benden C, Harpur-Sinclair O, Ranasinghe AS, Hartley JC, Elliott MJ, Aurora P. Surveillance bronchoscopy in children during the first year after lung transplantation: is it worth it? *Thorax.* 2007;62:57–61.
7. Visner GA, Faro A, Zander DS. Role of transbronchial biopsies in pediatric lung diseases. *Chest.* 2004;126:273–80.
8. Piccione J, Hysinger EB, Vicencio AG. Pediatric advanced diagnostic and interventional bronchoscopy. *Semin Pediatr Surg.* 2021;30:151065.
9. Ni C, Yu H, Han X, Meng C, Zhang Y. Clinical analysis of bronchoscopic cryotherapy in 156 pediatric patients. *Pediatr Int.* 2017;59:62–7.
10. Robinson M, Smiley M, Kotha K, Udoji T. Plastic bronchitis treated with topical tissue-type plasminogen activator and cryotherapy. *Clin Pediatr.* 2016;55:1171–5.
11. Kallam EF, Kasi AS, Patki R, Silva GL, Simon DM, Caltharp S, et al. Bronchoscopic interventions for plastic bronchitis in children without structural heart disease. *Eur J Pediatr.* 2021;180:3547–54.
12. Xu X, Ding H, Liu X, Zhu B, Feng Z. Emergency management for congenital tracheal stenosis with endoluminal stenting in pediatric intensive care units. *Ther Adv Respir Dis.* 2016;10:310–7.
13. Jiao A, Liu F, Lerner AD, Rao X, Guo Y, Meng C, et al. Effective treatment of post-intubation subglottic stenosis in children with holmium laser therapy and cryotherapy via flexible bronchoscopy. *Pediatr Investig.* 2019;3:9–16.
14. Hetzel J, Kumpf M, Hetzel M, Hofbeck M, Baden W. Cryorecanalization of an obstructed bronchial stent in a 12-year-old boy. *Respiration.* 2011;82:290–3.
15. Wang H, Zhang J, Li D, Zhang N, Li J, Mao J. Efficacy of bronchoscopic therapies for bronchial mucoepidermoid carcinoma in children: results from six patients. *Tumori.* 2015;101:52–6.
16. Ozgul MA, Toru U, Acat M, Ozgul G, Cetinkaya E, Dincer HE, et al. A rare tumor of trachea: inflammatory myofibroblastic tumor diagnosis and endoscopic treatment. *Respir Med Case Rep.* 2014;13:57–60.
17. Zhang L, Yin Y, Zhang J, Zhang H. Removal of foreign bodies in children's airways using flexible bronchoscopic CO<sub>2</sub> cryotherapy. *Pediatr Pulmonol.* 2016;51:943–9.
18. David AP, Xu MJ, Rosbe KW, Meyer AK, Gesthalter YB, Chan DK. Cryoprobe retrieval of an airway foreign body: a case report and literature review. *Int J Pediatr Otorhinolaryngol.* 2019;125:79–81.
19. Moslehi MA. Approach to foreign body aspiration in an infant using a cryoprobe. *Respir Case Rep.* 2020;9:4–7.
20. Davidsen JR, Skov IR, Louw IG, Laursen CB. Implementation of transbronchial lung cryobiopsy in a tertiary referral center for interstitial lung diseases: a cohort study on diagnostic yield, complications, and learning curves. *BMC Pulm Med.* 2021;21:67.
21. Hammer J, Trachsel D, Nicolai T, Weiss M, Eber E. Caution to use bronchoscopic CO<sub>2</sub> cryotherapy for foreign body removal in children. *Pediatr Pulmonol.* 2016;51:889–91.
22. Eber E, Anton-Pacheco JL, de Blic J, Doull I, Faro A, Nenna R, et al. ERS statement: interventional bronchoscopy in children. *Eur Respir J.* 2017;50:1700901.
23. Rasch D, Kubinger KD, Moder K. The two-sample t test: pre-testing its assumptions does not pay off. *Stat Pap.* 2011;52:219–31.
24. Ravaglia C, Wells AU, Tomassetti S, Gurioli C, Gurioli C, Dubini A, et al. Diagnostic yield and risk/benefit analysis of trans-bronchial lung cryobiopsy in diffuse parenchymal lung diseases: a large cohort of 699 patients. *BMC Pulm Med.* 2019;19:16.
25. Kuse N, Inomata M, Awano N, Yoshimura H, Jo T, Tone M, et al. Management and utility of transbronchial lung cryobiopsy in Japan. *Respir Investig.* 2019;57:245–51.
26. Gershman E, Fruchter O, Benjamin F, Nader AR, Rosengarten D, Rusanov V, et al. Safety of cryo-transbronchial biopsy in diffuse lung diseases: analysis of three hundred cases. *Respiration.* 2015;90:40–6.
27. Gershman E, Ridman E, Fridel L, Shtraichman O, Pertzov B, Rosengarten D, et al. Efficacy and safety of trans-bronchial cryo in comparison with forceps biopsy in lung allograft recipients: analysis of 402 procedures. *Clin Transplant.* 2018;32:e13221.
28. Hagmeyer L, Theegarten D, Wohlschlagler J, Hager T, Tremel M, Herkenrath SD, et al. Transbronchial cryobiopsy in fibrosing interstitial lung disease: modifications of the procedure lead to risk reduction. *Thorax.* 2019;74:711–4.
29. Hetzel J, Maldonado F, Ravaglia C, Wells AU, Colby TV, Tomassetti S, et al. Transbronchial cryobiopsies for the diagnosis of diffuse parenchymal lung diseases: expert statement from the cryobiopsy working group on safety and utility and a call for standardization of the procedure. *Respiration.* 2018;95:188–200.
30. Lang M, Brietzke SE. A systematic review and meta-analysis of endoscopic balloon dilation of pediatric subglottic stenosis. *Otolaryngol Head Neck Surg.* 2014;150:174–9.
31. Fernando HC, Dekeraty D, Downie G, Finley D, Sullivan V, Sarkar S, et al. Feasibility of spray cryotherapy and balloon dilation for non-malignant strictures of the airway. *Eur J Cardiothorac Surg.* 2011;40:1177–80.
32. Fernando HC, Sherwood JT, Krinsky W. Endoscopic therapies and stents for benign airway disorders: where are we, and where are we heading? *Ann Thorac Surg.* 2010;89:S2183–7.
33. Li AK, Ehrlich HP, Trelstad RL, Koroly MJ, Schattenkerk ME, Malt RA. Differences in healing of skin wounds caused by burn and freeze injuries. *Ann Surg.* 1980;191:244–8.
34. Bhora FY, Ayub A, Forleiter CM, Huang CY, Alshehri K, Rehmani S, et al. Treatment of benign tracheal stenosis using endoluminal spray cryotherapy. *JAMA Otolaryngol Head Neck Surg.* 2016;142:1082–7.
35. Mahajan AK, Patel PP, Garg R, Manley C, Ibrahim O, Mehta AC. Safety of laser and thermal therapy during rigid bronchoscopy using manual hand jet ventilation. *Surg Technol Int.* 2021;39:103–6.
36. Ratwani AP, Davis A, Maldonado F. Current practices in the management of central airway obstruction. *Curr Opin Pulm Med.* 2021;28:45–51.
37. Patel N, Patel M, Inja R, Krvavac A, Lechner AJ. Plastic bronchitis in adult and pediatric patients: a review of its presentation, diagnosis, and treatment. *Mo Med.* 2021;118:363–73.
38. Soyter T, Yalcin S, Emiralioglu N, Yilmaz EA, Soyter O, Orhan D, et al. Use of serial rigid bronchoscopy in the treatment of plastic bronchitis in children. *J Pediatr Surg.* 2016;51:1640–3.

39. Sriratanaviriyakul N, Lam F, Morrissey BM, Stollenwerk N, Schivo M, Yoneda KY. Safety and clinical utility of flexible bronchoscopic cryoextraction in patients with non-neoplasm tracheobronchial obstruction: a retrospective chart review. *J Bronchology Interv Pulmonol.* 2015;22:288–93.
40. Fruchter O, Kramer MR. Retrieval of various aspirated foreign bodies by flexible cryoprobe: in vitro feasibility study. *Clin Respir J.* 2015;9:176–9.
41. Swanson KL, Prakash UB, Midthun DE, Edell ES, Utz JP, McDougall JC, et al. Flexible bronchoscopic management of airway foreign bodies in children. *Chest.* 2002;121:1695–700.
42. Kim K, Lee HJ, Yang EA, Kim HS, Chun YH, Yoon JS, et al. Foreign body removal by flexible bronchoscopy using retrieval basket in children. *Ann Thorac Med.* 2018;13:82–5.
43. Endoh M, Oizumi H, Kanauchi N, Kato H, Ota H, Suzuki J, et al. Removal of foreign bodies from the respiratory tract of young

children: treatment outcomes using newly developed foreign-body grasping forceps. *J Pediatr Surg.* 2016;51:1375–9.

## SUPPORTING INFORMATION

Additional supporting information can be found online in the Supporting Information section at the end of this article.

**How to cite this article:** Schramm D, Freitag N, Kötz K, Iglesias-Serrano I, Culebras-Amigo M, Koblizek V, et al. Cryotherapy in the paediatric airway: Indications, success and safety. *Respirology.* 2022. <https://doi.org/10.1111/resp.14353>